

DOI: <https://doi.org/10.22141/2307-1257.13.2.2024.457>

Parth Bharat Solanki

Parul Institute of Medical Science and Research, Parul Sevashram Hospital, Parul University, Vadodara, Gujarat, India

Autologous vein graft in living donor kidney transplant (case report)

For citation: *Počki. 2024;13(2):172-174. doi: 10.22141/2307-1257.13.2.2024.457*

Abstract. Renal transplantation is the preferred treatment for end-stage renal disease, with vascular complications being a significant cause of graft dysfunction. Although many surgical methods are used to ensure the most effective possible vascular anastomosis, autologous saphenous vein grafting remains a less explored approach to renal transplantation. Chronic kidney disease often presents with complications related to impaired renal perfusion, necessitating interventions to improve blood flow to the kidneys. Herein, we present a case report detailing the utilization of autologous saphenous grafting to establish an anastomosis between the renal vein and external iliac vein in a patient with chronic kidney disease with maintenance hemodialysis twice a week. This case report indicates the potential and prospective advantages of using autologous saphenous grafting for intricate renal vein reconstructions in patients with chronic kidney disease.

Keywords: chronic kidney disease; renal transplantation; living donor kidney transplant; autologous vein

Introduction

Chronic kidney disease remains a prevalent health concern, necessitating various therapeutic approaches including renal transplantation. Kidney transplantation stands as the gold standard for the management of end-stage renal disease, offering improved quality of life and enhanced survival rates compared to dialysis. Surgical interventions may sometimes present unique challenges. In such cases, alternative strategies are required to overcome anatomical limitations and ensure successful vascular reconstruction. Vascular complications contributing to renal dysfunction often demand innovative surgical solutions. The successful outcome of kidney transplantation is heavily reliant on meticulous surgical techniques, especially concerning vascular anastomosis, ensuring optimal blood supply to the transplanted kidney. However, surgical complexities may arise, particularly concerning vascular mismatch between the donor renal vein and the recipient's external iliac vein. When the donor renal vein length is insufficient for direct anastomosis, alternative strategies become imperative to ensure adequate blood supply and optimal graft function. One such innovative approach involves the utilization of autologous saphenous grafting to bridge the vascular gap, offering a potential solution in such challenging scenarios. This case

focuses on the surgical approach, procedural intricacies, postoperative outcomes, emphasizing the viability and effectiveness of innovative techniques in addressing anatomical challenges during kidney transplantation.

Case report

A 28-year-old male with chronic kidney disease who was on maintenance hemodialysis was prepared for kidney transplant surgery using a living kidney donor transplant, the donor being his mother. The renal vein was cut shorter than intended during the ongoing kidney procurement process from the living donor. However, the surgeons were certain that the recipient kidney would have complete vascularization upon anastomosis of blood vessels. Following the procedure, it became apparent that the small renal vein presented a challenge in creating an impeccable vascularization to ensure proper alignment and adequate blood flow to the transplanted kidney. Given the urgency of the patient's condition and the necessity for an immediate intervention, autologous saphenous vein grafting was proposed as an alternative method to facilitate successful vascular anastomosis. Patient's own saphenous vein was utilized to create a vascular conduit, allowing for a seamless connection between the donor renal vein and the recipient's external iliac

© 2024. The Authors. This is an open access article under the terms of the Creative Commons Attribution 4.0 International License, CC BY, which allows others to freely distribute the published article, with the obligatory reference to the authors of original works and original publication in this journal.

For correspondence: Dr. Parth Bharat Solanki MBBS, MS, Mch, Associate Professor, Department of Cardiothoracic and Vascular Surgery, Parul Institute of Medical Science and Research, Parul Sevashram Hospital, Parul University, Vadodara, Gujarat, India; e-mail: drsmithbharat@gmail.com; tel.: +919825798542

Full list of author's information is available at the end of the article.

vein successfully restoring blood flow to the kidney. Careful attention was given to the appropriate sizing and preparation of the graft to ensure optimal blood flow and minimize the risk of complications. Post-transplant Doppler was done (Fig. 1, 2, 3).

Discussion

Chronic kidney disease remains a prevalent health concern, necessitating various therapeutic approaches including renal vein revascularization. Surgical intervention may present unique challenges. In such cases, alternative strategies are required to overcome anatomical limitations and ensure successful vascular reconstruction. Although uncommon, vascular damage after kidney transplantation might result in significant hemorrhage, graft loss, and limb ischemia. Efficient decision-making in excising the graft, flushing with cold preservation solution, and returning to the ice can preserve the kidney transplant and provide more time for a more accurate and controlled healing of the vascular lesion [4]. Vascular complications with various etiologies occur in 3–15 % of patients receiving kidney transplantation. These include transplant renal artery stenosis, transplant renal artery or vein thrombosis, biopsy-induced vascular damage,

pseudoaneurysm development and hematomas embolus causing renal infarction or dissections [2, 9]. Numerous renal veins with thin walls and tiny diameters can make it challenging to select the major drainage vein especially during right kidney transplant surgery. When the renal vein is inadequate in length, the branches are ligated and clipped, and one vein is extended to perform an anastomosis. Reconstructions generally involve an end-to-side anastomosis with the external iliac vein [10].

There are several ways to construct vascular anastomoses, including autogenous internal iliac artery bypass, polytetrafluoroethylene grafts, third-party vascular allografts, and saphenous vein grafts. An alternative blood supply to the transplanted kidney may be the internal iliac artery in certain circumstances of anatomic variation or an atheromatous external iliac artery. However, because there is a chance that using the internal iliac artery could compromise the pelvis’s distal blood supply, which could lead to impotence, sexual dysfunction, and buttock claudication, it is less frequently utilized [2]. This case demonstrates the importance of adaptable surgical methods in dealing with various anatomical variances that arise during kidney transplantation. In circumstances when typical vascular anastomosis techniques may not be feasible, or in managing complex vascular anatomy, the use of autologous saphenous vein grafts in renal transplantation offers an alternate and creative approach. Previous studies on autologous saphenous vein transplant renal artery repair have been reported and that has raised concerns about late consequences, including the development of pseudoaneurysms and stenosis [1, 3]. Miyuchi Y. et al. (2021) reported first case study of renal vein reconstruction using Y-shaped saphenous vein grafting, indicating an effective solution for treating anastomosis-related complications and getting a successful venous reconstruction [10]. The utilization of autologous saphenous grafting as an interposition graft between the renal vein and external iliac vein in this case of inadequate donor renal vein length represents a novel and effective approach in managing challenging vascular reconstructions in patients with chronic kidney disease. Further studies and long-term follow-ups are warranted to validate the durability and effectiveness of

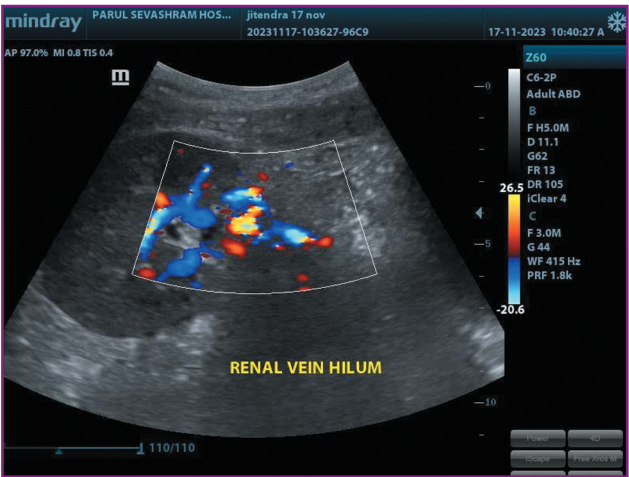


Figure 1. Doppler of renal vein hilum

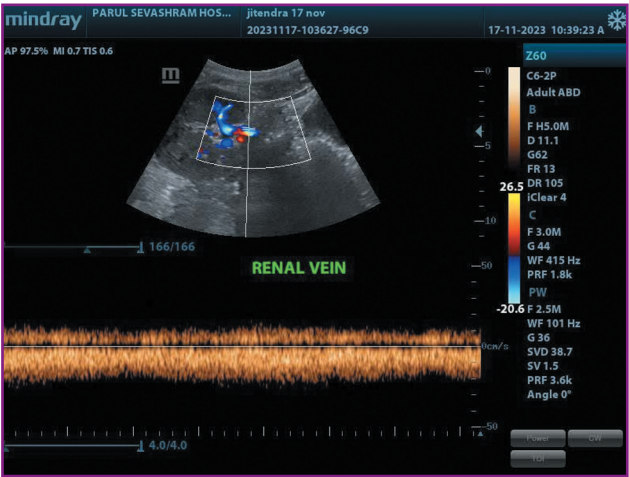


Figure 2. Renal vein Doppler

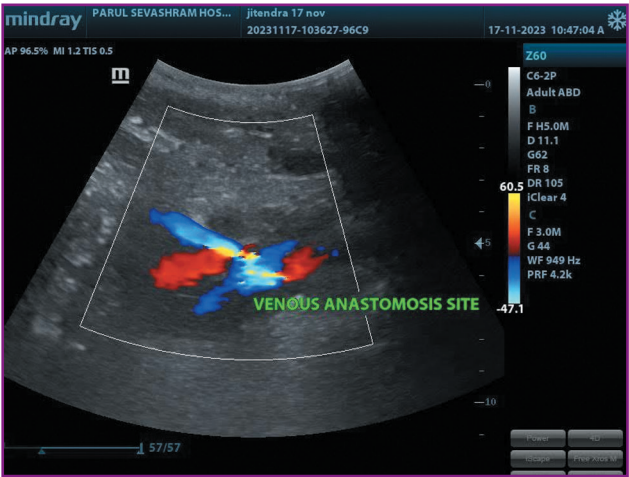


Figure 3. Anastomotic site Doppler

this surgical approach in preserving renal function and mitigating the progression of chronic kidney disease in similar patient populations.

Acknowledgments. I wish to thank Parul Institute of Medical Science and Research, Parul Sevashram Hospital, Parul University for encouraging me to publish the manuscript.

References

1. Hanlon LV, Agostinho N, D'Souza K, et al. Renal Transplant Artery Autologous Saphenous Vein Graft Aneurysms: Late Presentation and the Need for Recall and Surveillance. *Exp Clin Transplant*. 2020 Nov;18(6):725-728. doi: 10.6002/ect.2020.0301.
2. Ho CERH, So WZ, Wong J, Tiong HY. Successful repair of transplant renal artery aneurysm (TRAA). *BMC Urol*. 2023 Jul 31;23(1):129. doi: 10.1186/s12894-023-01280-z.
3. Hwang JC, Moritz MJ. Case Report: The Use of Cryopreserved Saphenous Vein in Reconstruction of Transplant Renal Artery Dissection. *Transplant Direct*. 2023 Dec 12;10(1):e1546. doi: 10.1097/TXD.0000000000001546.
4. Mekeel KL, Halldorson JB, Berumen JA, Hemming AW. Kidney clamp, perfuse, re-implant: a useful technique for graft salvage after vascular complications during kidney transplantation. *Clin Transplant*. 2015 Apr;29(4):373-8. doi: 10.1111/ctr.12526.
5. Rahneimai-Azar AA, Gilchrist BF, Kayler LK. Independent risk factors for early urologic complications after kidney transplantation. *Clin Transplant*. 2015 May;29(5):403-8. doi: 10.1111/ctr.12530.
6. Nino-Torres L, Garcia-Lopez A, Patino-Jaramillo N, Giron-Luque F, Nino-Murcia A. Risk Factors for Urologic Complications After Kidney Transplantation and Impact in Graft Survival. *Res Rep Urol*. 2022 Sep 28;14:327-337. doi: 10.2147/RRU.S371851.
7. Buttigieg J, Agius-Anastasi A, Sharma A, Halawa A. Early urological complications after kidney transplantation: An overview. *World J Transplant*. 2018 Sep 10;8(5):142-149. doi: 10.5500/wjt.v8.i5.142.
8. Lushina N, Lee A, Cuadra S, Whang M, Sun H. External Iliac Artery Dissection During Renal Transplantation: A Case Report and Literature Review. *Transplant Proc*. 2019 Mar;51(2):538-540. doi: 10.1016/j.transproceed.2018.12.021.
9. Mayhew M, Solomon R, LaGuardia H, Shaw K, Arenas J, Hranjec T. Vascular Complications in Renal Transplantation: Surgical Salvage of Renal Artery Dissection. *Transplant Direct*. 2022 May 26;8(6):e1340. doi: 10.1097/TXD.0000000000001340.
10. Miyauchi Y, Noda T, Miura N, Kikugawa T, Saika T. Venous reconstruction using a Y-shaped saphenous vein in kidney transplantation: A report of three cases. *IJU Case Rep*. 2021 Feb 16;4(3):146-149. doi: 10.1002/iju5.12266.

Received 25.03.2024

Revised 29.04.2024

Accepted 30.04.2024 ■

Information about author

Dr. Parth Bharat Solanki, Associate Professor, Department of Cardiothoracic and Vascular Surgery, Parul Institute of Medical Science and Research, Parul Sevashram Hospital, Parul University, Vadodara, Gujarat, India

Conflicts of interests. Author declares the absence of any conflicts of interests and own financial interest that might be construed to influence the results or interpretation of the manuscript.

Parth Bharat Solanki

Parul Institute of Medical Science and Research, Parul Sevashram Hospital, Parul University, Vadodara, Gujarat, India

Використання аутологічного венозного трансплантата під час трансплантації нирки від живого донора (клінічний випадок)

Резюме. Трансплантація нирки є методом вибору при лікуванні термінальної ниркової недостатності, а судинні ускладнення є важливою причиною дисфункції трансплантата. Хоча задля забезпечення максимальної ефективності судинного анастомозу використовується безліч хірургічних методів, аутологічна трансплантація підшкірної вени залишається менш вивченим підходом до трансплантації нирки. Хронічна хвороба нирок часто супроводжується ускладненнями, пов'язаними з порушенням перфузії, що потребує втручання для покращення притоку крові до нирок. У цій роботі ми представляємо клінічний випадок, що докладно описує вико-

ристання аутологічного підшкірного трансплантата для створення анастомозу між нирковою веною та зовнішньою клубовою веною в пацієнта з хронічною хворобою нирок, який знаходиться на підтримуючому гемодіалізі двічі на тиждень. Цей випадок вказує на потенційні та перспективні переваги використання аутологічного підшкірного трансплантата при складних реконструкціях ниркових вен у пацієнтів із хронічною хворобою нирок.

Ключові слова: хронічна хвороба нирок; трансплантація нирки; трансплантація нирки від живого донора; аутологічна вена